

"Base template details - Not to be changed"

Template Id	Template Name	Version No.	Release Date
TMT025	Training Manual Document	1	DD/MM/YY

Design Document

GENERAL_2016_BODY_PARTS_001.V1


[Document Related To]

Amendment sheet

Version No.	Release Date	Modified by Date	Reviewed by Date	Authorized by Date	Remarks
1.0		Resource DD/MM/YY			Initial Version

Table of Contents

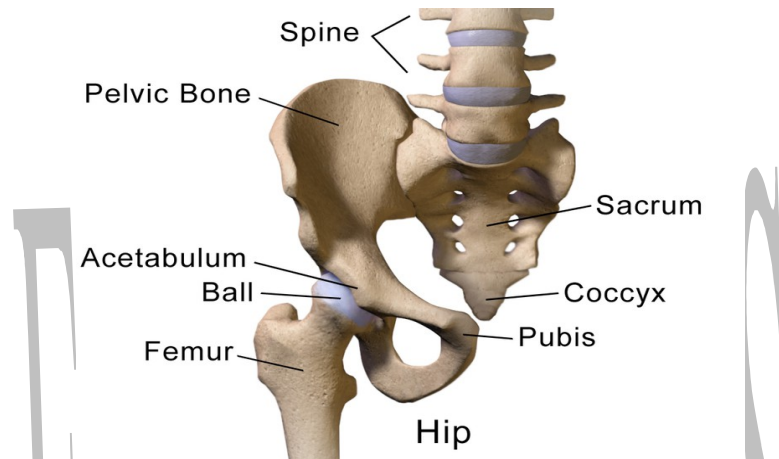
TABLE OF CONTENTS.....	2
1.HIP.....	3
1.1. OVERVIEW.....	3
1.2. FUNCTIONS.....	3
1.3. MAJOR DISEASES AND SYMPTOMS.....	3
1.4. RADIOLOGY EXAMINATIONS.....	4
1.4.1 APPLICABLE RADIOLOGY EXAMINATIONS.....	4
1.4.2 MRI (MAGNETIC RESOURCE IMAGING).....	5
1.4.3 CT (COMPUTED TOMOGRAPHY).....	5
1.5. REFERENCES.....	7
1.6. GLOSSARY.....	7



1. HIP

1.1. Overview

A joint forms where two or more bones meet. The hip joint is a ball-and-socket type joint and is formed where the thigh bone (femur) meets the three bones that make up the pelvis. Large ligaments, tendons, and muscles around the hip joint (called the joint capsule) hold the bones (ball and socket) in place and keep it from dislocating.



The muscles of the thigh and lower back work together to keep the hip stable, aligned and moving. The iliofemoral, pubofemoral, and ischiofemoral ligaments completely encompass the hip joint and form the joint capsule. The iliofemoral ligament is the strongest ligament in the body.

1.2. Functions

1. The hip provides the main connection between the leg and the skeletal structure of the trunk and pelvis.
2. The hip joint specifically connects the femur of the leg with the hip bone.
3. The primary function of the hip is to support the weight of the body during standing, walking and running.

1.3. Major Diseases and Symptoms

S. No	Disease	Symptoms
1	Osteoarthritis: Osteoarthritis occurs when inflammation and injury to a joint cause a breaking down of cartilage tissue. In turn, that breakdown causes pain, swelling, and deformity.	<ol style="list-style-type: none">1. Joint aching and soreness, especially with movement2. Pain after overuse or after long periods of inactivity3. Stiffness after periods of rest4. Joint swelling

2	Fracture: A hip fracture is a break in the upper quarter of the femur (thigh) bone. The extent of the break depends on the forces that are involved. The type of surgery used to treat a hip fracture is primarily based on the bones and soft tissues affected or on the level of the fracture.	<ol style="list-style-type: none"> 1. incredibly painful injury 2. Not able to move the effected leg let alone walk 3. Swelling 4.lack of adequate circulation to the hip and groin area
3	Bone tumor: A bone tumor (also spelled bone tumour) is a neoplastic growth of tissue in bone. Abnormal growths found in the bone can be either benign (noncancerous) or malignant (cancerous). Average five-year survival in the United States after being diagnosed with bone and joint cancer is 67%.	<ol style="list-style-type: none"> 1. Weakening of the involved bone can lead to fractures 2. Extremely painful. 3. swelling or a mass may be felt in the hip. 4. Enlarged lymph nodes, fevers, chills, night sweats, fatigue and a general ill feeling
4	Dislocation: Hip dislocation symptoms are commonly caused by large amounts of force being placed on the lower extremities. The most common way that this injury occurs is through motor vehicle accidents.	<ol style="list-style-type: none"> 1. legs that turn outward or appear to differ in length 2. limited range of motion 3. folds on their legs and buttocks that are uneven when their legs extend

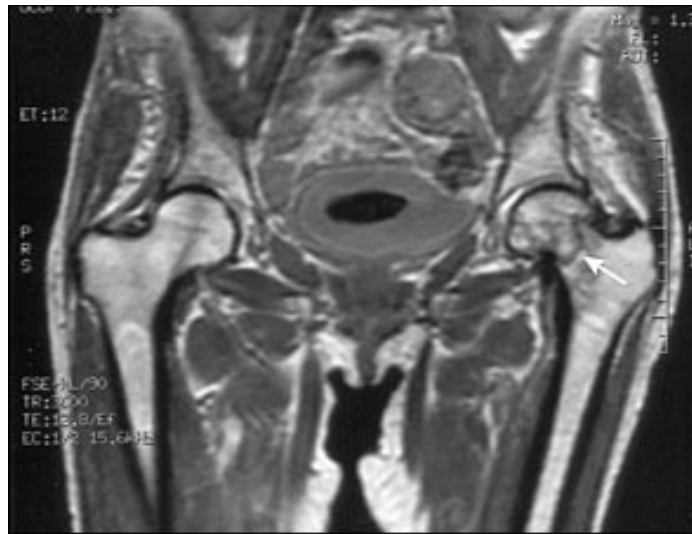
1.4. Radiology Examinations

1.4.1 Applicable Radiology Examinations

Radiology Examination Name	Is Applicable (Yes/No)
CR	No
CT	Yes
DS	No
DR	No
DX	No
MR	Yes
NM	No
OT	No
PT	No
RG	No
RF	No
SC	No
US	Yes
XA	Yes

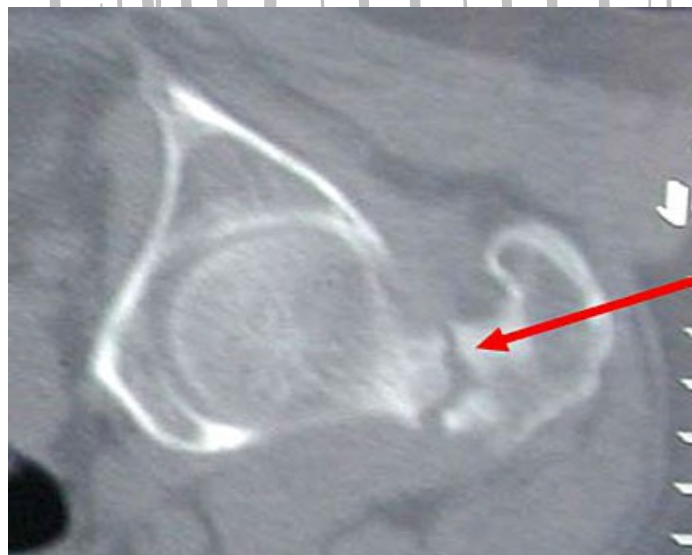1.4.2 MRI (Magnetic Resource Imaging)

Magnetic resonance imaging study of the hip joints in the patient. This radiograph confirmed the presence of a left nondisplaced femoral neck fracture (arrow).



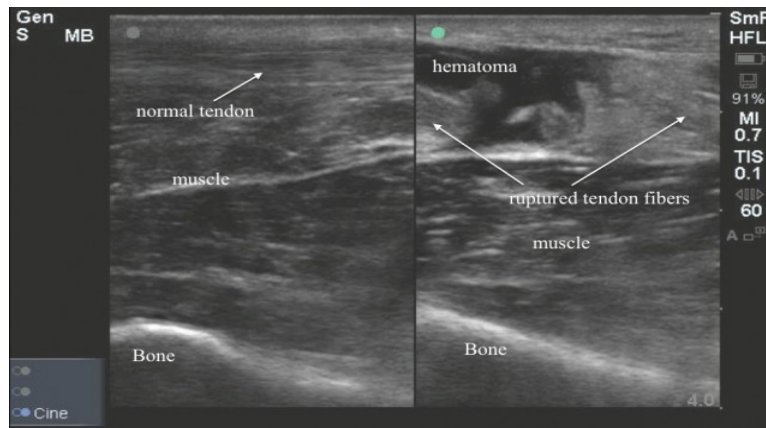
1.4.3 CT (Computed Tomography)

CAT is widely available, rapid, and easily tolerated by patients with potential hip injuries. computed tomography (or CT) scan, this noninvasive test combines X-ray equipment with sophisticated computers to produce multiple images of the hip. The computer can combine the individual images to create a three-dimensional view of the hip. CT scan shows soft tissues such as ligaments and muscles more clearly than traditional X-rays do, so it is more useful for diagnosing certain hip problems.



1.4.5 US (Ultra Sound)

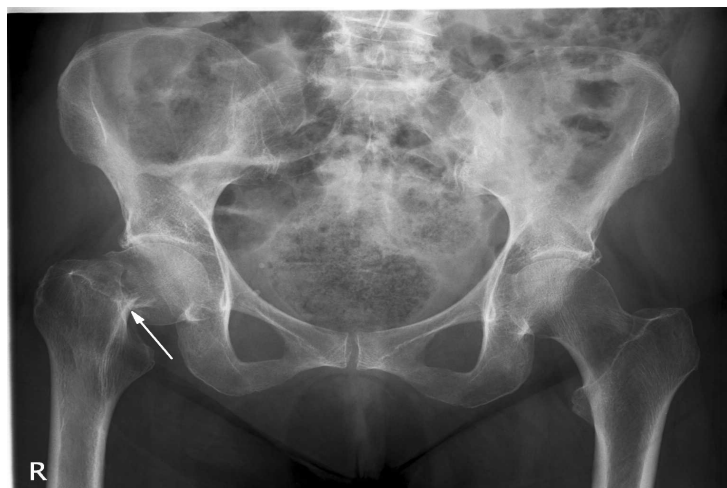We propose the use of bedside ultrasound examination of the hip as a screening tool for occult hip fractures. To measure the sensitivity and specificity of ultrasound exam of the hip in diagnosing or ruling out occult hip fractures.



1.4.6. XA(X-Ray Angiography)

The femoral neck appears to be shortened superiorly, and the edge of the femoral head appears to be impacted on top of the femoral neck (*arrow*). However, the fracture is not well characterized on the radiograph.

1. **joint alignment:** Problems with alignment can cause or worsen changes that result from arthritis in the hip.
2. **joint space:** Narrowing of the space between the two bones, which are normally covered by cartilage, can be a sign of arthritis and its severity.
3. **bone spurs:** Bony over growths at the joint are a sign of osteoarthritis.
4. **bone structure:** Problems of the bone, including fractures, osteonecrosis and Paget's disease of the bone can often be seen on X-ray.



1.5. References

S. No	URL
1	https://acsearch.acr.org/docs/3082587/Narrative/
2	https://www.ncbi.nlm.nih.gov/books/NBK83026/
3	https://www.ebmedicine.net
4	http://www.boneandjoint.org.uk/content/jbjsbr/72-B/3/379.full.pdf
5	http://www.arthritis.org/about-arthritis/where-it-hurts/hip-pain/diagnosis/hip-pain-xray-mri-catscan.php
6	http://www.healthline.com/health/hip-disorders#Symptoms3

1.6. Glossary

S.no	Term	Description
1	Angiography	Either of the two bones that form the sides of the pelvis Angiograph is the test where dyes
2	Tendons	similar to ligaments
3	Cartilage	a resilient and smooth elastic tissue
4	bone spurs	bony growth formed on normal bone.
5	femur	thigh bone .