

**"Base template details - Not to be changed"**

Template Id	Template Name	Version No.	Release Date
TMT025	Training Manual Document	1	DD/MM/YY

## Design Document

GENERAL\_2016\_BODY\_PARTS\_001.V1

[Document Related To]

Amendment sheet

Version No.	Release Date	Modified by Date	Reviewed by Date	Authorized by Date	Remarks
1.0		Resource DD/MM/YY			Initial Version

## Table of Contents

<b>TABLE OF CONTENTS.....</b>	<b>2</b>
<b>1.PELVIS.....</b>	<b>3</b>
1.1. OVERVIEW.....	3
1.2. FUNCTIONS.....	4
1.3. MAJOR DISEASES AND SYMPTOMS.....	4
1.4. RADIOLOGY EXAMINATIONS.....	4
1.4.1 APPLICABLE RADIOLOGY EXAMINATIONS.....	4
1.4.2 MRI ( ).....	5
1.4.3 CT ( COMPUTED TOMOGRAPHY).....	5
1.5. REFERENCES.....	6
1.6. GLOSSARY.....	6



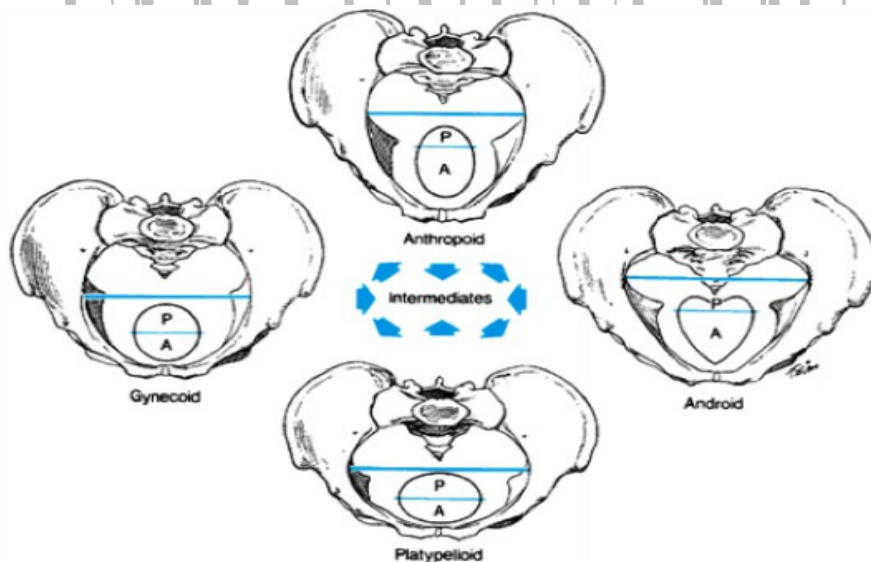
# 1. PELVIS

## 1.1. Overview

The Pelvis, or pelvic girdle, is an irregular bony structure at the base (caudal end) of the spine. Pelvis is formed by a ring of bones formed by the sacrum (with the coccyx) and the innominate bones (made up of three bones fused together: the ilium, the ischium and the pubis).

The ilium is the largest and uppermost part of the pelvis, the ischium is the posterior-inferior (the part you sit on) and the pubis is the anterior part. The two innominates are joined anteriorly at the pubis symphysis and posteriorly to the sacrum. The three bones that constitutes the innominate come together in the acetabulum; the concavity forming the socket of the hip joint.

### 1.1.1. Types of Pelvis



There are 4 types of pelvis:

- Gynaecoid** - normal female pelvis, round with enlarged transverse diameter
- Android** - Normal male pelvis, heart shaped
- Anthropoid** - Long anterior/posterior diameter
- Platypeloid** - long transverse diameter

## 1.2. Functions

1. Supports the weight of the body through the vertebral column and passes that force onto the hip bones .
2. Receives ground forces during walking and transmits them upward toward the vertebral column.
3. Supports and protects pelvis viscera.
4. Provides attachment site for muscles.
5. Makes up bony portion of birth canal

### 1.3. Major Diseases and Symptoms

S. No	Disease	Symptoms
1	<b>PID</b> - Pelvic inflammatory disease (PID) is an infection and inflammation of a woman's pelvic organs including the uterus (womb), Fallopian tubes (tubes), ovaries, and cervix	1. Abnormal vaginal discharge. 2. Fever and chills 3. Painful urination 4. Nausea and vomiting 5. Painful sexual intercourse 6. Abnormal menstrual bleeding

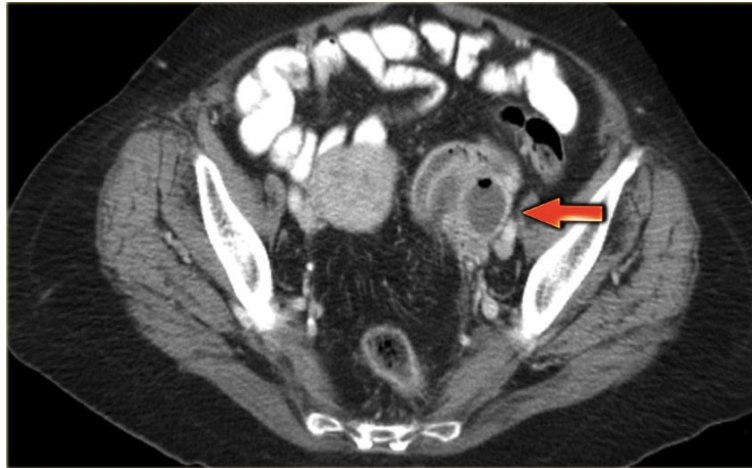### 1.4. Radiology Examinations

#### 1.4.1 Applicable Radiology Examinations

Radiology Examination Name	Is Applicable (Yes/No)
CR	No
CT	Yes
DS	No
DR	No
DX	No
MR	No
NM	No
OT	No
PT	No
RG	No
RF	No
SC	No
US	Yes
XA	No

#### 1.4.2 MRI ()

MRI show an ill-defined adnexal mass containing fluid with various signal intensities

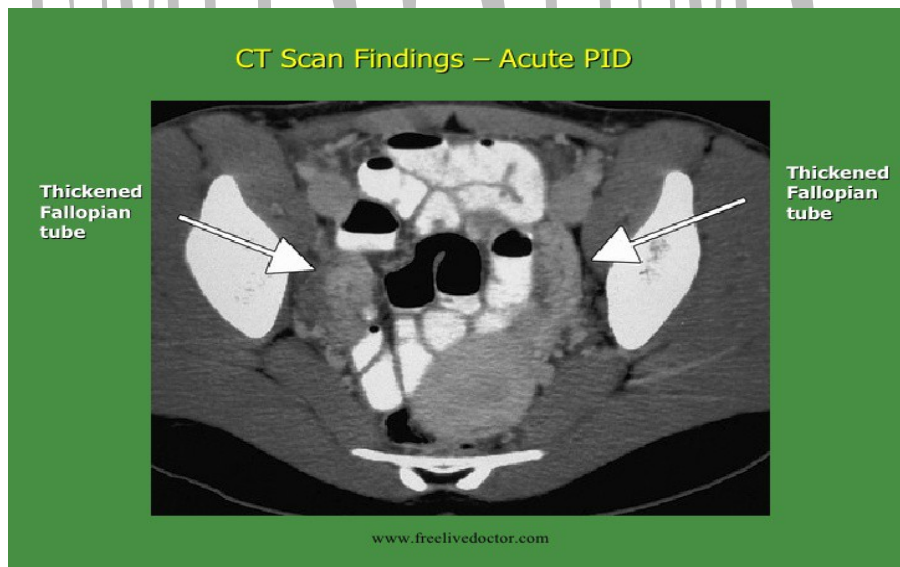


This test may be used to look for:

1. Sensitivity 95%
2. Specificity 89%
3. Accuracy 93%

### 1.4.3 CT (Computed Tomography)

CT shows a diffusely-enhancing ill-defined pelvic mass, which may be difficult to differentiate from malignancy. CT scanning is very sensitive for the detection of pelvic pathology.

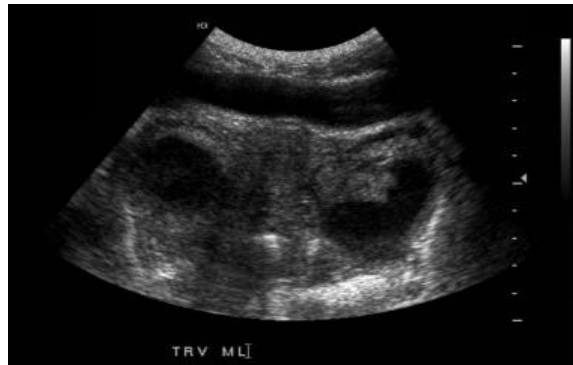

This test may be used to look for:

1. Sensitivity < 65%
2. Specificity < 90%
3. Accuracy 84%

### 1.4.5 US (Ultra Sound)

Transabdominal ultrasound scan. This image demonstrates an echogenic region within the endometrium with dirty shadowing, a finding that is compatible with air in the endometrium and endometritis.



This test may be used to look for:

1. Sensitivity 81%
2. Specificity 78%
3. Accuracy 80%

### 1.5. References

S. No	URL
1	<a href="http://emedicine.medscape.com/article/404537-overview">http://emedicine.medscape.com/article/404537-overview</a>
2	<a href="http://www.jultrasoundmed.org/content/31/11/1713.full">http://www.jultrasoundmed.org/content/31/11/1713.full</a>
3	<a href="http://www.webmd.com/women/guide/sexual-health-your-guide-to-pelvic-inflammatory-disease#1">http://www.webmd.com/women/guide/sexual-health-your-guide-to-pelvic-inflammatory-disease#1</a>
4	<a href="http://www.medicinenet.com/image-collection/hip_picture/picture.htm">http://www.medicinenet.com/image-collection/hip_picture/picture.htm</a>
5	<a href="http://www.healthpages.org/anatomy-function/hip-structure-function-common-problems/">http://www.healthpages.org/anatomy-function/hip-structure-function-common-problems/</a>
6	<a href="http://www.healthline.com/health/hip-disorders#Symptoms3">http://www.healthline.com/health/hip-disorders#Symptoms3</a>

### 1.6. Glossary

S.no	Term	Description
1	Innominate	Either of the two bones that form the sides of the pelvis
2	Acetabulum	A concave surface of the pelvis.
3	Vertebral	Vertebrae are the 33 individual bones that interlock with each other to form the spinal column
4	Pelvis viscera	Maintenance of continence as part of the urinary
5	Endometritis	Inflammation of the endometrial lining of the uterus.
6	Endometrium	he inner lining of the uterus.
7	Uterus	A major female hormone-responsive reproductive sex organ of human
8	Cervix	Cylinder-shaped neck of tissue